

Management of rectal foreign bodies

M. Verducruyssen³, Ch. Simoens¹, J.F. Nyst², N. Van De Winkel¹, P. Mendes Da Costa¹, V. Thill¹

(1) Department of Digestive, Thoracic and Laparoscopic Surgery and of (2) Gastro-Enterology, (3) Medical student, CHU Brugmann, ULB, Brussels, Belgium.

Abstract

The presence of foreign bodies inserted into the rectum is not an uncommon situation. Precise guidelines for the management and extraction of these foreign bodies are not frequently described in the literature.

Anal access, whether endoscopic or surgical, varies depending on the type of foreign bodies, their size and morphology, and their location in the lower digestive tract.

In this report, we describe a case of three rectal foreign bodies that necessitated a mixed endoscopic and surgical approach, and provide a review of the literature. (*Acta gastroenterol. belg.*, 2010, 73, 274-277).

Key words : rectal foreign bodies ; management ; endoscopy ; surgery.

Abbreviations : computed tomography (CT).

Introduction

It is not rare to encounter patients in the emergency department who have accidentally or voluntarily inserted a foreign body into their digestive tract.

Here we report on the case of a patient who inserted three foreign bodies into his rectum, two of which were extracted by endoscopy, and the third of which necessitated laparotomy.

Case report

The patient was a 64-year old man with a medical history significant for treated arterial hypertension. He did not smoke, use alcohol, or illicit drugs. The patient presented to the emergency department complaining of abdominal pain and occasional hematochezia.

On questioning, the patient reported constipation for greater than one week. He also complained of relatively localized periumbilical pain and small quantities of bright red blood on attempts at bowel movement.

On physical examination, the patient was hemodynamically stable, afebrile, and in good overall physical condition. Abdominal palpation revealed a hard, well-defined, mobile mass on the left side and in the iliac fossa ; examination was also positive for diffuse tenderness without rigidity or rebound. Abdominal percussion revealed the persistence of a hepatic dullness and auscultation revealed normal peristalsis.

Anterior-posterior and lateral plain abdominal radiograph were conducted (Fig. 1) and showed several foreign bodies in the recto-sigmoid area.

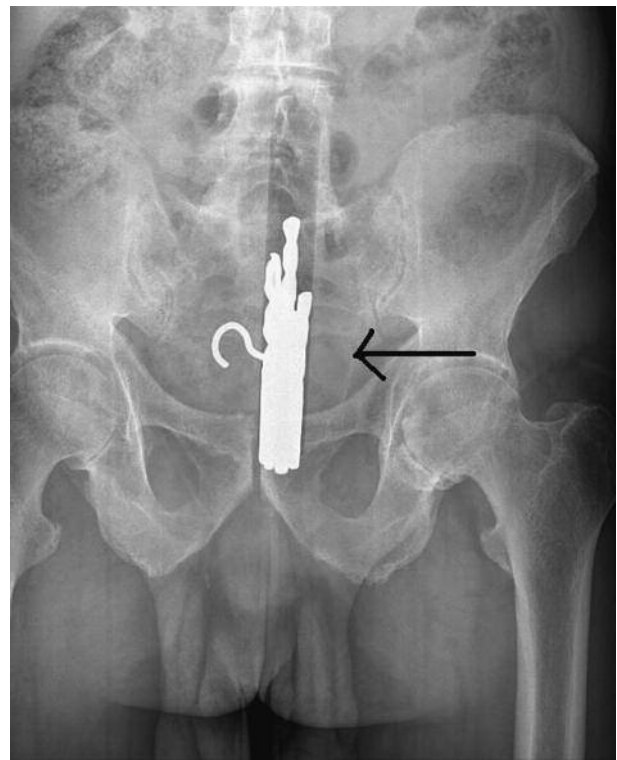


Fig. 1. — Frontal plain abdomen x-ray view

On further questioning, the patient revealed that these items were a piece of soap, a box containing drill bits, and a screw hook. He reported that he inserted these objects in this precise order, for the first two, to relieve his constipation and, for the last, in an attempt to extract what he had already inserted into his rectum. He would not specify how long these objects were lodged in his digestive tract.

A CT scan was performed to provide precise imaging of the objects' position and to exclude the possibility of perforation ; imaging showed no pneumoperitoneum (Fig. 2).

Correspondence to : P. Mendes da Costa, Department of Digestive, Thoracic and Laparoscopic Surgery, CHU Brugmann, Place A. Van Gehuchten, 4, B-1020 Brussels, Belgium. E-mail : pierre.mdc@chu-brugmann.be

Submission date : 18/03/2009

Acceptance date : 15/10/2009

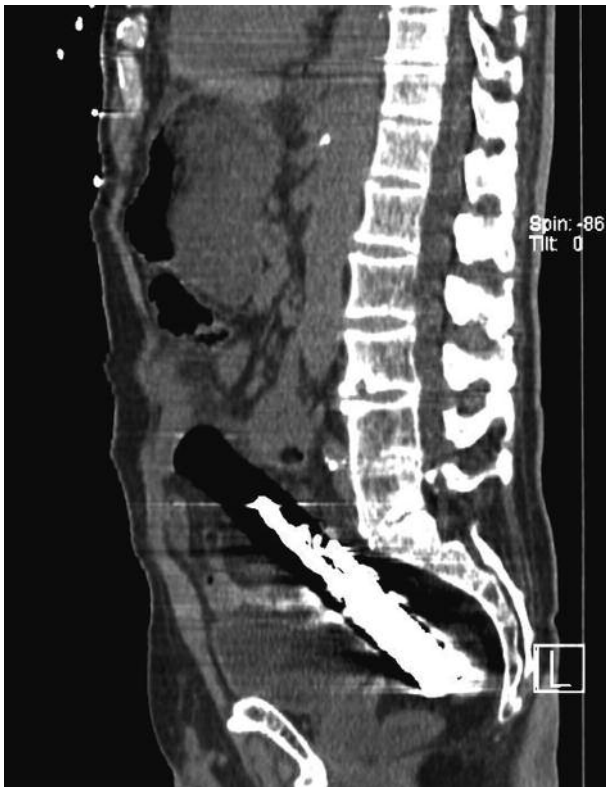

Fig. 2. — CT scan : no pneumoperitoneum visible

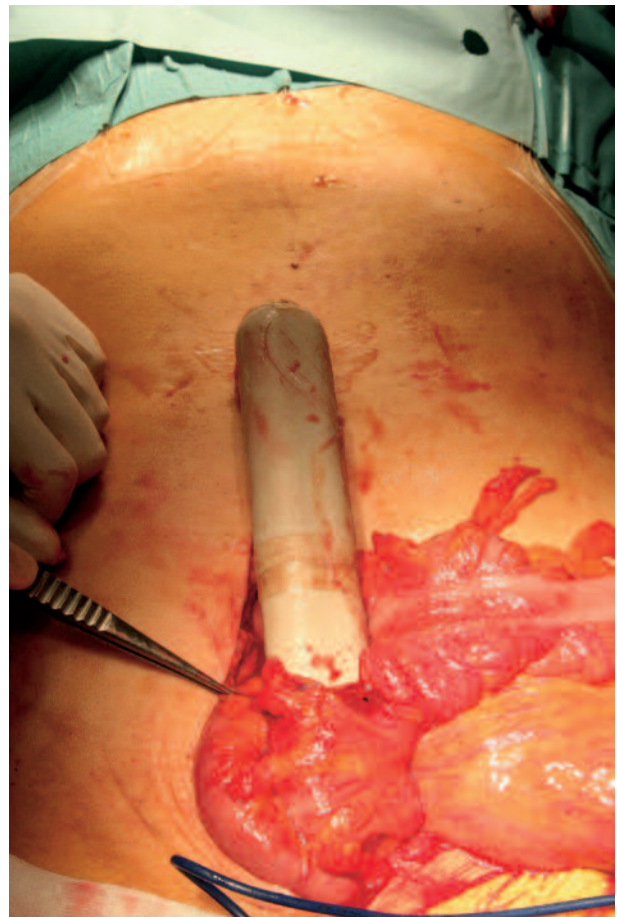

Fig. 3. — Intraoperative view (no stool visible)

The biology did not show any sign of inflammation.

Rectosigmoidoscopy was performed without preparation under general anesthesia after receiving the results.

An experienced endoscopist extracted the soap and the hook with a flexible endoscope and a 20 mm loop.

The box of drill bits could not be removed due to the absence of surface friction that would have permitted a firm grip.

During these maneuvers, no visible damage to the mucosal surface was identified. Soon after endoscopy, abdominal swelling appeared and pre-hepatic dullness resolved.

A plausible hypothesis for these clinical findings is that colonic perforation was already present prior to endoscopy secondary to pressure from the foreign body on the colon wall ; the perforation was not apparent clinically or radiographically because the object was literally embedded in the wall, providing a water- and airtight seal of the perforated wall.

The decision was then made to perform laparoscopy. This allowed location of the box, which leaves via three-quarters of the digestive structures (Fig. 3) The foreign body was successfully removed. Since the colon was empty of stool, basic two-layer repair and cleansing irrigation were performed. Post-operative follow up was uneventful and the patient was discharged 13 days post-operatively.

Discussion

A review of the literature shows that a broad array of surgical and non-surgical techniques is used for the extraction of foreign bodies from the rectum, with no clear guidelines as to the optimum approach. The choice of technique is most often left to the creativity of the consulting physician. However, one of the commonly acknowledged rules is that patients should be treated in the least invasive manner after clinical and radiological evaluation (1). The absence of perforation is suggested based on clinical examination but can only be confirmed by imaging. In this case, abdominal CT should be performed.

In the case presented here, imaging was negative for perforation because the foreign body completely filled the bowel lumen ; perforation was initially present but not radiographically apparent because of this tight fit. After endoscopic insufflation, the perforation became apparent.

An algorithm for non-surgical management has been proposed by Koornstra J.J. *et al.* (2) (Fig. 4).

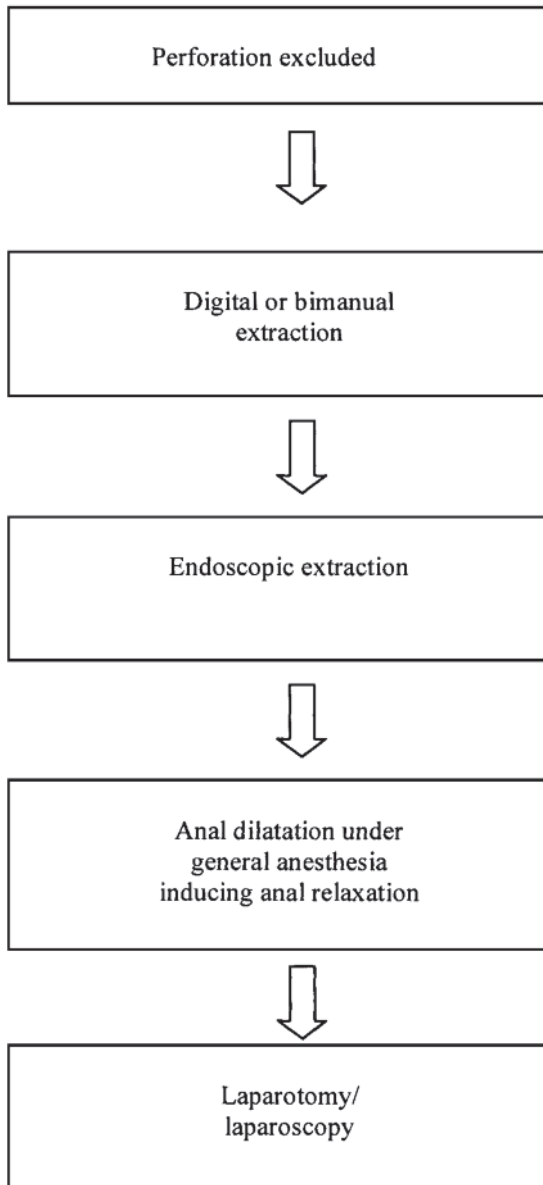


Fig. 4. — Algorithm of non-surgical techniques according to Koornstra J.J. *et al.* (2).

They specify that when there is no perforation, the first step is to attempt digital extraction of the foreign body with or without cleansing, in various positions as deemed necessary. In the case of failure, bimanual manipulation (one hand on the abdomen guiding the body and one or two fingers in the rectum attempting to grasp the body) may be attempted in patients whose BMI is less than 25 kg/m² (3).

There are no reports in the literature of the precise success rate of manual extract, but it seems that a majority of foreign bodies are removed successfully with this technique (1,2,6,7). On the other hand, if relaxation of the anal sphincters is not adequate, local anesthesia, spinal or general, may be used and increases the success

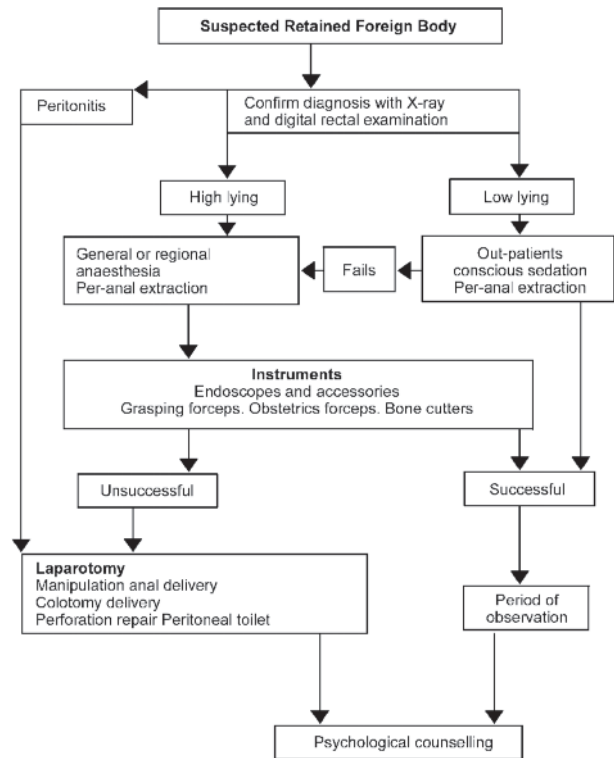


Fig. 5. — Algorithm according to Clarke D.L. *et al.* (7)

rate of non-invasive procedures. If digital removal is unsuccessful, endoscopy under local-regional or general anesthesia is conducted.

Another algorithm is proposed by Clarke *et al.* (Fig. 5, ref. 7), which does not differ from Koornstra’s algorithm other than the inclusion of psychological counselling.

Several extraction tools have been proposed, including the recent and relatively successful use of a dilatation balloon ordinarily used for treatment of achalasia ; the balloon is slid above the foreign body then inflated, thereby making it possible to bring the foreign body down without trauma. This technique is not designed for sharp or pointed objects that could injure the intestinal wall during extraction (4).

Surgery should be considered when these methods fail. In various articles (4-10) that have appeared in the past ten years, it appears that a reasonable and unanimous choice is open or coelioscopic surgery when a perforation is suspected and the patient’s hemodynamic condition is unstable or when conservative methods are unsuccessful. Some authors (4) also recommend consideration of laparotomy as the first method for extraction when the foreign body has been present for longer than 24 hours. Even though no evidence of an adequate level has been advanced, according to Jeffrey *et al.* (5) who now has the largest series, that there is an association between location of the foreign body and the need for

Table I. — Literature dat

Authors	Number	Sex ratio	Age in years	Kind of foreign body	Circumstances	Non surgical approach	Laparotomy	Colostomy	Deciding algorithm
Ruiz del Castillo <i>et al.</i> (1)	17	NS	NS	NS	NS	10	7	5	–
Jan J. Koornstra <i>et al.</i> (2)	Case report	male	19	container	sexual	1	0	0	+
Tsuyoshi K. <i>et al.</i> (3)	Case report	male	79	Light bulb	sexual	1	0	0	–
Kingsley A.N. <i>et al.</i> (4)	51	NS	NS	NS	NS	51	–	–	–
Lake P.J. <i>et al.</i> (5)	93	NS	NS	NS	NS	70	23	NS	–
Rodriguez Hermosa J.I. <i>et al.</i> (6)	30	20 males 10 females	42.5	26 different objects	sexual in 14 cases	14	16	6	–
Clarke D.L. <i>et al.</i> (7)	13	Only males	2-66	varied	sexual	8	5	1	+
Kouraklis G. <i>et al.</i> (8)	21	NS	NS	NS	NS	20	1	NS	–
Sharma H. <i>et al.</i> (9)	Case report	Male	38	apple	sexual	1	–	–	–
Humes D. <i>et al.</i> (10)	Case report	Male	28	Spirit bottle	sexual abuse	1	–	–	–

+ : present ; – : absent, NS : not specified.

laparotomy. In fact, patients presenting with a foreign body located higher (in the sigmoid colon, for example) have been, in the majority of cases, surgically treated. In this same series, the authors showed an association between the size of the object (> 10 cm), the duration of retention (> 2 days), and the indication for surgical intervention.

After extraction of the foreign body, if there is stercoral contamination, either a Hartmann-type colectomy or a colon repair with discharge colostomy should be performed (6). However, in certain situations associated with clean colons (such as in the case presented above), primary re-establishment of digestion continuity can be considered. Table I summaries data from the literature.

In the absence of official guidelines, it would seem that certain broad guiding principles could be followed in the management of intra-rectal foreign bodies. A minimally invasive or endoscopic approach is recommended as a first recourse, with or without anesthesia. This approach is adequate treatment in most cases. In case of endoscopic failure, or large foreign bodies located high up or long-term insertion (more than 24 hours) surgical extraction (by laparotomy or laparoscopy) is indicated.

References

1. RUIZ DEL CASTILLO J., SELLÈS DECHENT R., MILAN SCHEIDIN M., ZUMARRAGA NAVAS P., ASENSIO ARANA F. Colorectal trauma caused by foreign bodies introduced during sexual activity : Diagnosis and management. *Rev. Esp. Enferm. Dig.*, 2001, **10** : 631-634.
2. KOORNSTRA J.J., WEERSMA R.K. Management of rectal foreign bodies : Description of a new technique and clinical practice guidelines. *World J. Gastroenterol.*, 2008, **14** (27) : 4403-6.
3. TSUYOSHI K., TOSHIKI W., HIROKAZU N. Impaction of a rectal foreign body : What is the final approach before surgery ? *Dis. Colon Rectum*, 2006, **50** : 262-3.
4. KINGSLEY A.N., ABCARIAN H. Colorectal foreign bodies : management update. *Dis. Colon Rectum*, 1985, **28** : 941-4.
5. LAKE J.P., ESSANI R., PETRONE P., KAISER A.M., ASENSIO J., BEART R.W. JR. Management of retained colorectal foreign bodies : Predictors of operative interventions. *Dis. Colon Rectum*, 2004, **47** : 1694-8.
6. RODRIGUEZ-HERMOSA J.L., CODIN-CAZADOR A., RUIZ-B., SIRVENT J.M., ROIG J., FARRÉS R. Management of foreign bodies in the rectum. *Colorectal. Dis.*, 2007, **9** : 543-8.
7. CLARKE D.L., BUCCIMAZZA I., ANDERSON F.A., THOMSON S.R. Colorectal foreign bodies. *Colorectal. Dis.*, 2005, **7** : 98-103.
8. KOURAKLIS G., MISIAKOS E., DOVAS N., KARATZAS G., GOGAS J. Management of foreign bodies of the rectum : Report of 21 cases. *J. R. Coll. Surg. Edinb.*, 1997, **42** : 246-7.
9. SHARMA H., BANKA S., WALTON R., MEMON M.A. A novel technique for nonoperative removal of round rectal foreign bodies. *Tech. Coloproctol.*, 2007, **11** : 58-9.
10. HUMES D., LOBO D.N. Removal of a rectal foreign body by using a Foley catheter passed through a rigid sigmoidoscope. *Gastrointest. Endosc.*, 2005, **62** : 610.